Brain Stimulation 12 (2019) 797–799

Contents lists available at ScienceDirect

Brain Stimulation

journal homepage: http://www.journals.elsevier.com/brain-stimulation

Light at the end of the tunnel: Improvement of post-stroke visual field defect after open-label navigated perilesional rTMS

Keywords:
rTMS
Stroke
Visual field defect
Perimetry
Navigated

Cortical visual field defects (cVFD) usually show a narrow window of recovery not exceeding a few months. In some studies recovery was mostly in the first 10 days of insult followed by decrease in recovery rate that nearly plateaus 10–12 weeks after insult, and only 5% of patients will show full recovery of their visual field [1–5].

Areas of residual vision (ARV) at the borders of those of absolute blindness are the functional counterpart of partially damaged brain regions at the perilesional areas [6].

In the current study, we hypothesize that stimulation of the perilesional, seemingly healthy brain tissue, close to infarcted area would result in clinical improvement. To achieve this precise targeting, we used navigated rTMS.

This is an open-label pilot case series study conducted in the neuromodulation unit, neurology department, Ain Shams University after approval by Ain Shams University faculty of medicine local research ethics committee.

A total of 12 patients with cortical visual field defect (cVFD) secondary to ischemic stroke participated in the study after giving an informed written consent. All patients were above 18 years, with a duration of illness of at least 3 months.

Patients were excluded if they had cVFD due to lesions outside the visual cortex or had any contraindication to rTMS.

Assessment was done prior to and after 16 rTMS sessions using National Eye Institute Visual Functioning Questionnaire-25 (VFQ-25) and automated perimetry to examine 30-degree field of vision from center of fixation using the full threshold 30-2 and obtain the mean deviation (MD) and visual field index.

An MRI Brain T1WI with 0.9 mm sections was used to create a three-dimensional virtual head model for each patient. The target for stimulation was then determined and marked. Four targets were selected to be along the outer border in the perilesional area in the nearest seemingly-healthy tissue to the involved visual cortex. Each target was stimulated for 4 consecutive sessions of 1000 pulses for a total of 4000 pulses.

Stimulation parameters: Motor threshold was detected in the abductor pollicis brevis according to the method described by Rossini et al. [7]. Patients received a total of 16, every other day sessions of rTMS at 10 Hz frequency, 90% of motor threshold, 25 trains − 40 pulses per train with 20 seconds intertrain interval and a total of 1000 pulses. The coil handle was directed downwards at 45° of the sagittal plain to ensure that the induced electric field be perpendicular to the underlying gyrus (Fig. 1) [8]. MagVenture MagPro X100 repetitive transcranial magnetic stimulator with Magoption and a figure of eight coil of 13 cm diameter was used.

Eight patients completed the study and a ninth patient completed the VFQ-25 interview but not the perimetry. Duration of illness ranged from 3 to 24 months (mean = 6.56 months). Results showed statically significant improvement in MD (Baseline -18.58 ± 6.75 dB, follow up -14.20 ± 6.48 dB) ($p = 0.046$) and VFQ-25 (Baseline 303.59 ± 151.10, follow up 444.60 ± 170.37) ($p = 0.001$). Visual field index showed important improvement as well (Baseline $45.56\% \pm 20.18$, follow up $58.17\% \pm 17.58$) ($p = 0.057$). Two patients did not show any improvement.

The change in MD was variable ranging from 2.19 to 12.77 dB. This variability could not be explained by the duration or severity of cVFD at baseline as both showed no significant correlation with the change in MD ($r = 0.43$, $p = 0.287$), ($r = 0.43$, $p = 0.283$), respectively. An example of visual field at baseline and after treatment is shown in Fig. 1. Side effects were minimal, two patients reported transient headache that did not require treatment and one patient developed transient vertigo and tinnitus that resolved spontaneously.

We assume that the improvement observed could be attributed to rTMS rather than spontaneous recovery, since patients had already reported a stationary course before therapy followed by a relatively quick improvement over the short period of applying rTMS.

We encountered what has been described by several authors as "*the mismatch problem*"; a mismatch observed in some patients between improvement in the perimetry and subjective improvement reported by the patient [6]. The mismatch problem can be explained by improvement in other qualities of vision not being measured by perimetry [9].

Lack of controls is the most remarkable limitation. A follow up randomized case control trial is currently underway.

Abbreviations: ARV, areas of residual vision; MD, mean deviation; rTMS, repetitive transcranial magnetic stimulation; cVFD, cortical visual field defects; VFI, visual field index; VFQ-25, visual functioning questionnaire-25.

https://doi.org/10.1016/j.brs.2019.01.018
1935-861X/© 2019 Elsevier Inc. All rights reserved.

Downloaded for Anonymous User (n/a) at Egyptian Knowledge Bank from ClinicalKey.com by Elsevier on October 29, 2020.
For personal use only. No other uses without permission. Copyright ©2020. Elsevier Inc. All rights reserved.

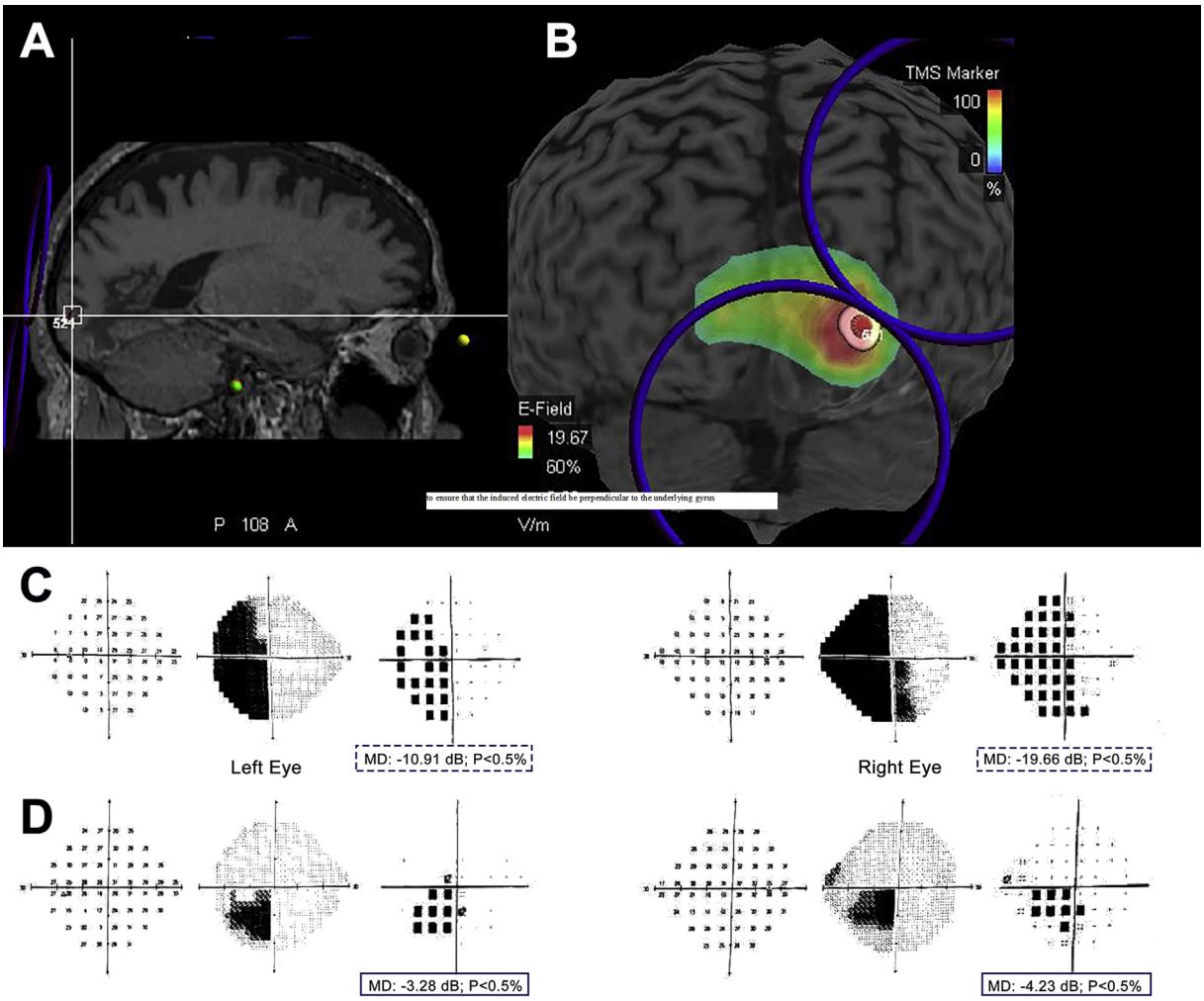

Fig. 1. MRI brain and Automated Perimetry. A, Both the perilesional stimulation target (crosshair) and coil orientation can be seen. B, Head model showing the perilesional target (small white circle) and coil orientation (figure of 8) during a TMS session. C, Automated perimetry at baseline showing complete homonymous hemianopia (MD shown within a dashed box). D, Automated perimetry after receiving 16 sessions of perilesional rTMS (MD shown within a solid box).

Sixteen sessions of high frequency perilesional navigated rTMS led to improvement in cVFDs both functionally and by perimetry even after 3 months of stroke.

Conflicts of interest

None.

Funding sources

None.

Acknowledgments

Ain Shams neuromodulation research lab and its equipment used in this study were established through a grant from Science & Technology Development Fund (STDF) in Egypt [project ID 2893, capacity building]. The funding source played no role in the planning, analysis, or writing of this article.

References

[1] Gray CS, French JM, Bates D, Cartlidge NEF, Venables GS, James OFW. Recovery of visual fields in acute stroke: homonymous hemianopia associated with adverse prognosis. Age Ageing 1989;18:419–21. https://doi.org/10.1093/ageing/18.6.419.
[2] Zhang X, Kedar S, Lynn MJ, Newman NJ, Biousse V. Natural history of homonymous hemianopia. Neurology 2006;66:901–5. https://doi.org/10.1212/01.wnl.0000203338.54323.22.
[3] Cassidy TP, Bruce DW, Lewis S, Gray CS. The association of visual field deficits and visuo-spatial neglect in acute right-hemisphere stroke patients. Age Ageing 1999;28:257–60. https://doi.org/10.1093/ageing/28.3.257.
[4] And KT, Kolmel HW. Patterns of recovery from homonymous hemianopia subsequent to infarction in the distribution of the posterior cerebral artery. Neuro Ophthalmol 1991;11:33–9. https://doi.org/10.3109/01658109109009640.
[5] Poggel DA. Unusual spontaneous and training induced visual field recovery in a patient with a gunshot lesion. J Neurol Neurosurg Psychiatry 2001;70:236–9. https://doi.org/10.1136/jnnp.70.2.236.
[6] Sabel BA, Henrich-Noack P, Fedorov A, Gall C. Vision Restoration After Brain and Retina Damage: the "Residual Vision Activation Theory", 192; 2011. https://doi.org/10.1016/B978-0-444-53355-5.00013-0.
[7] Rossini PM, Barker AT, Berardelli A, Caramia MD, Caruso G, Cracco RQ, et al. Non-invasive electrical and magnetic stimulation of the brain, spinal cord and roots: basic principles and procedures for routine clinical application.

Downloaded for Anonymous User (n/a) at Egyptian Knowledge Bank from ClinicalKey.com by Elsevier on October 29, 2020.
For personal use only. No other uses without permission. Copyright ©2020. Elsevier Inc. All rights reserved.

Report of an IFCN committee. Electroencephalogr Clin Neurophysiol 1994;91:79–92. https://doi.org/10.1016/0013-4694(94)90029-9.
[8] Janssen AM, Oostendorp TF, Stegeman DF. The coil orientation dependency of the electric field induced by TMS for M1 and other brain areas. J NeuroEng Rehabil 2015;12:47. https://doi.org/10.1186/s12984-015-0036-2.
[9] Mueller I, Poggel D, Kenkel S, Kasten E, Sabel B. Vision restoration therapy after brain damage: subjective improvements of activities of daily life and their relationship to visual field enlargements. Vis Impair Res 2003;5:157–78. https://doi.org/10.1080/1388235039048692.

Nevine M. El Nahas*
Ain Shams Neuromodulation Research Lab, Neurology dep, Faculty of Medicine, Ain Shams University, Cairo, Egypt

Ahmed M. Elbokl
Ain Shams Neuromodulation Research Lab, Neurology dep, Faculty of Medicine, Ain Shams University, Cairo, Egypt
E-mail address: Ahmed.elbokl@med.asu.edu.eg.

Randa M. Amin
Ain Shams Neuromodulation Research Lab, Neurology dep, Faculty of Medicine, Ain Shams University, Cairo, Egypt
E-mail address: randamoustafa@med.asu.edu.eg.

Tamer M. Roushdy
Ain Shams Neuromodulation Research Lab, Neurology dep, Faculty of Medicine, Ain Shams University, Cairo, Egypt
E-mail address: Tamer.roushdy@med.asu.edu.eg.

Aya Ahmed Ashour
Ain Shams Neuromodulation Research Lab, Neurology dep, Faculty of Medicine, Ain Shams University, Cairo, Egypt
E-mail address: Aya.ashour85@gmail.com.

Ahmed Zaki Akl
Ain Shams Neuromodulation Research Lab, Neurology dep, Faculty of Medicine, Ain Shams University, Cairo, Egypt
E-mail address: dr.ahmedzaki@outlook.com.

Eman Hamid Abd Eldayem
Ain Shams Neuromodulation Research Lab, Neurology dep, Faculty of Medicine, Ain Shams University, Cairo, Egypt
E-mail address: Eman.hamed@med.asu.edu.eg.

Shahinaz M. Helmy
Ain Shams Neuromodulation Research Lab, Neurology dep, Faculty of Medicine, Ain Shams University, Cairo, Egypt
E-mail address: shahinaz.helmy@med.asu.edu.eg.

Mohamed Nowara
Al-Mashreq Eye Center, Cairo, Egypt
E-mail address: m_nowara00@yahoo.com.

Tamer H. Emara
Ain Shams Neuromodulation Research Lab, Neurology dep, Faculty of Medicine, Ain Shams University, Cairo, Egypt
E-mail address: thmfe@yahoo.com.

* Corresponding author. 58 Nakheel Compound, Shorouk City, Cairo, 11837, Egypt.
E-mail address: nevine_elnahas@med.asu.edu.eg (N.M. El Nahas).

10 January 2019
Available online 31 January 2019

Downloaded for Anonymous User (n/a) at Egyptian Knowledge Bank from ClinicalKey.com by Elsevier on October 29, 2020.
For personal use only. No other uses without permission. Copyright ©2020. Elsevier Inc. All rights reserved.